

SKULL BASE OSTEOMYELITIS IN AN IMMUNOCOMPETENT HOST: A RARE AND ATYPICAL PRESENTATION

Authors: Arushi Kumar (1), Kanika Arora (2), Nazrin Hameed (2), Abhishek Dubey (2), Manjul Muraleedharan (2), Kalyan Chidambaram (2), Mohd Aqib (2), Ravisankar Manogaran (4).

Authors Affiliations: (1.) Junior Resident Department of ENT, Nalanda Medical College, and Hospital, Patna, Bihar. (2.) Senior Resident Neuro otology, Department of Neurosurgery, SGPGIMS, Lucknow, UP. (4.) Associate Professor Neurotology, Department of Neurosurgery, SGPGIMS, Lucknow, UP.

ABSTRACT

INTRODUCTION

Skull base osteomyelitis (SBO) is a rare clinical entity, more so in immunocompromised patients as compared to immunocompetent ones. We report an unusual case of SBO in an immunocompetent male patient in his 40s, who presented to us with the complains of left ear discharge & decreased hearing.

MATERIAL AND METHOD

A male patient in his early 40s, with no comorbidities, presented with deviation of angle of the mouth towards the right side for seven months, along with the inability to close the left eye for three months.

CONCLUSION

The classical signs & symptoms of SBO like nocturnal pain, ear discharge, granulations in EAC & otitis externa not responding to treatment were absent in this patient. 7th, 9th, 10th cranial nerve palsy was also noted. Imaging showed destructive lesions with inflammation. This case is being reported for its rarity and atypical presentation after an extensive search of the literature.

Keywords: Skull base, Osteomyelitis, immunocompromised

INTRODUCTION

Skull base osteomyelitis(SBO) is a rare clinical

entity with a chronic course with high morbidity and mortality, more so in immunocompromised patients as compared to immune- competent ones. The classical signs & symptoms of SBO like nocturnal pain, ear discharge, granulations in EAC & otitis externa usually helps us to diagnose such cases. This case is being reported for its rarity and atypical presentation such that the diagnosis was solely based on post operative histopathology.

CASE REPORT

A male patient in his early 40s, with no comorbidities, presented with deviation of angle of the mouth towards the right side for seven months, along with the inability to close the left eye for three months. He had history of left ear discharge with decreased hearing on the left side since childhood. The facial nerve symptoms were of insidious onset and gradually progressed over months. There is a change in the history of change in voice which improved over some time. The patient never had a history of dysphagia, nasal regurgitation, or saliva drooling. He received topical and systemic antibiotics for the above symptoms, to which he partially responded; however, he had a persistent facial nerve palsy for which he was referred to our department. He had a history of tobacco chewing for 20 years, from which he has abstained for the past five years. There is no history of contact with tuberculosis or similar ailment in the family

On examination, right ear drum was un-

remarkable, whereas a central perforation was evident on the left side with minimal mucoid discharge. Mastoid and tragal tenderness was absent. Nystagmus was absent.

An obvious deviation of the angle of the mouth towards the right side at rest, absence of forehead wrinkles on the left side on frowning, an inability to close left eye with effort along with an absence of any perceptible movement suggested a Left sided Grade 6 House Brackman infra nuclear facial nerve palsy.

Upon local examination of oral cavity, oropharynx and larynx, gag reflex was found to be decreased on the left side, uvula shifted to the right side and palatal movements absent on the left side. A well-compensated left vocal cord palsy was present. Tongue movements were normal. Spinal accessory nerve function was monotonous on both sides. All other cranial nerve functions were also intact.

Tuning fork tests revealed a left sided conductive hearing loss. Rinnie's was negative on the left side, Weber's was also lateralised to the left. Absolute Bone Conduction was normal as compared to the examiner, all three indicative of a left sided conductive deafness. Pure tone audiometry was suggestive of a left sided conductive hearing loss of 38 dB (Figure 1); right sided hearing was within normal limits. Routine blood investigations were all within normal limits; ESR was 12, glycosylated hemoglobin was 5.7. An ear swab was sent for culture sensitivity, which was reportedly sterile.

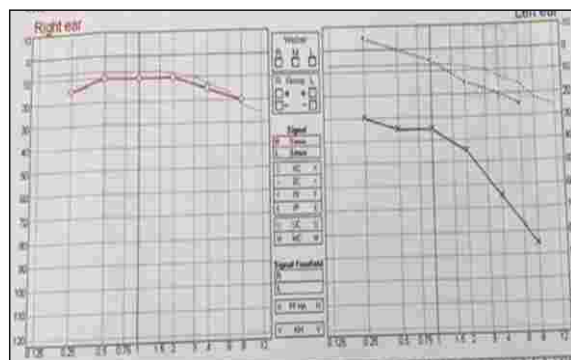


Figure 1: Shows the Pure tone audiometry

findings of this patient. A left sided conductive hearing loss of 38 dB is recorded. Right sided hearing is within normal limits.

CT was suggestive of erosion of left squamous, mastoid, lateral petrous and part of petro-clival region. It shows heterogenous destruction where continuity of bone is maintained at places. (Figure 2)

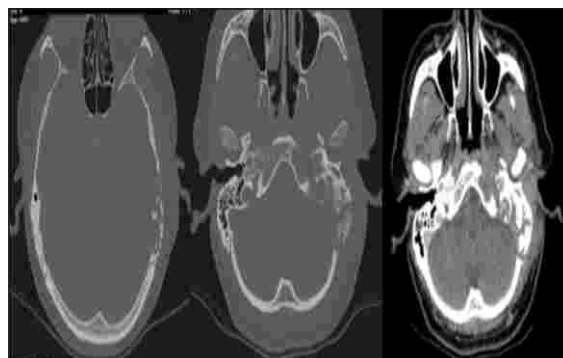


Figure 2: CT temporal bone axial cuts was suggestive of erosion of left squamous, mastoid, lateral petrous and part of petro-clival region. It shows heterogenous destruction where continuity of bone is maintained at places.(W:2800, L:600) (left 2- bony cuts; rightmost- soft tissue window)

MRI shows heterogenous soft tissue mass in the same area of mastoid petrous region, middle ear region, region of Inner ear & petrous temporal bone. Infratemporal structures are also destroyed. This mass has heterogenous contrast enhancement which is patchy at places. It also suggests an adjacent dural enhancement. At places, there are nodular enhancements suggestive of granulomatous pathology. This mass seems to be occupying the region of cerebellopontine angle & lateral medullary cistern region. (Figure 3)

Based on clinical examination and investigations, the possibility of malignant pathology, invasive fungal infection, and tuberculosis was considered as the differential diagnosis, given the extensive destruction of the mastoid and involvement of the lower cranial nerves. Patient underwent left mastoid exploration with removal of necrotic

bone and granulations over sigmoid sinus, jugular process, mastoid tip and part of tympanic temporal bone sent for HPE and fungal smear. Facial nerve was engulfed in necrotic tissue at the level of stylomastoid foramen. Middle ear and ossicles were intact; type 1 cartilage tympanoplasty was done. HPE was suggestive of fragments of bony trabeculae with intervening tissue showing mixed inflammatory cell infiltrate comprising of plasma cells, lymphocytes & occasional neutrophils. Foci of micro- abscess and collection of histiocytic giant cells was also identified. Prominent vascular proliferation, no evidence of fungal elements, granuloma or malignancy. Thereby, patient was treated on lines of osteomyelitis with intravenous antibiotics, analgesics and eye care.

Patient was discharged on oral antibiotics, analgesics on postoperative day 3 with persistent grade 6 facial palsy and tarsorrhaphy. After two months, audiometry showed mild conductive hearing loss with an average of 25 db; at the same time, the patient was advised for plastic surgery opinion for the facial reanimation procedures as well as regular speech and swallowing therapy.

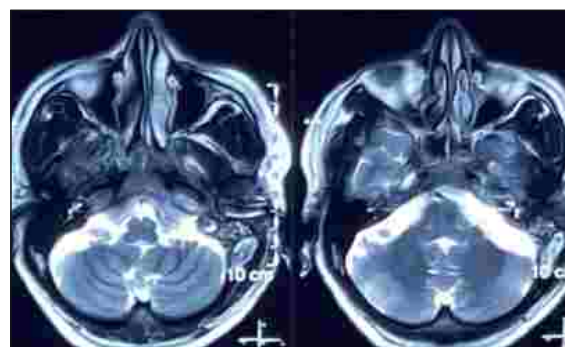
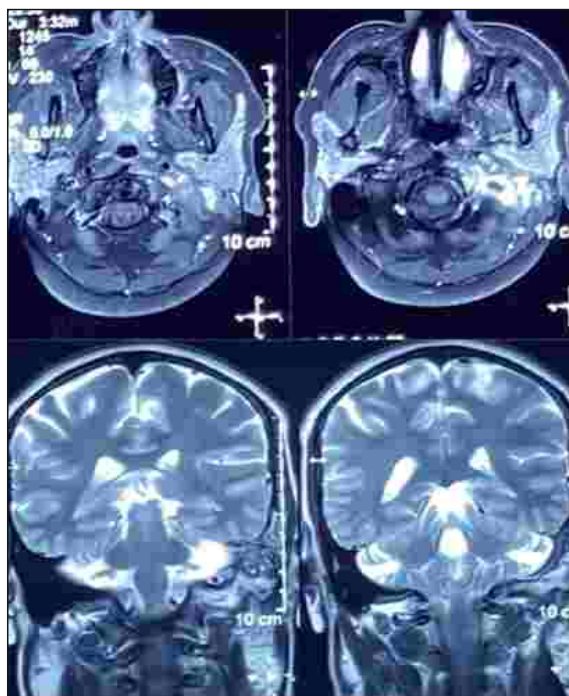


Figure 3: CEMRI showing heterogenous soft tissue mass in the same area of mastoid petrous region, middle ear region, region of Inner ear & petrous temporal bone. Infratemporal structures are also destroyed. This mass has heterogenous contrast enhancement which is patchy at places. It also suggests an adjacent dural enhancement. At places, there are nodular enhancements suggestive of granulomatous pathology. This mass seems to be occupying the region of cerebellopontine angle & lateral medullary cistern region.(From top to bottom- T1 with contrast Axial cuts; T2 coronal cuts; T2 axial cuts)

DISCUSSION

Skull base osteomyelitis is an uncommon clinical entity in immunocompetent individuals. It is typically seen in individuals like diabetics, patients with end stage renal disease, hematopoietic malignancy & AIDS. The principal pathogen implicated in the aetiology of SBO is *Pseudomonas aeruginosa*, although others like *Staphylococcus* sp, *Streptococcus* sp, *Keibseilla* have also been reported. Both immunocompromised as well as immunosuppressed individuals can present with fungal osteomyelitis. Atypical SBO might not present with the classical clinical features of SBO like nocturnal headache/facial pain, otorrhea, granulation tissue in EAC and otitis externa not responding to treatment like in our patient. HPE report in our patient had features of inflammation with giant cells. Close differentials for giant cell rich lesions of temporal bone are Langerhan cell histiocytosis, Sarcoidosis, Giant cell tumor, chondroblastoma,

Giant cell reparative granuloma [1] which have overlapping clinical and radiological features.

Most common differential diagnosis of SBO is Malignancy of temporal bone- primary or metastatic. A combination of Galactomannan assay & imaging findings are required when tissue diagnosis is not possible as there is no single pathognomic test to diagnose or rule out SBO.[2] Atypical SBO in immunocompetent person in the setting of headache, absent of cranial neuropathy, elevated ESR and abnormal imaging should arouse suspicion of Tubercular SBO.[3]

The imaging techniques used are contrast enhanced CT, MRI, and nuclear imaging. CT shows irregular destruction of temporal bone & involvement of otic capsule in later stages. However, there should be more than 30% of bone loss for CT to detect osteomyelitis. Technetium 99 scan is useful for early diagnosis & Gallium Scan is useful to note the response to treatment.[4] SBO possesses a high mortality & morbidity, therefore prompt diagnosis & appropriate treatment are critical. Long term Antibiotics and/or antifungals form the mainstay of treatment, along with management of the underlying causative factor.[4]

CONCLUSION

The typical clinical scenario of a SBO involves immunocompromised individuals, a high index of suspicion is required to diagnose it in immunocompetent patients with atypical complaints. The radiological findings closely mimic malignancy, necessitating the need for a histological diagnosis. Prompt diagnosis and management of the patient are of utmost importance in reducing mortality and morbidity associated with SBO, even if atypical.

REFERENCES

1. Martinez AP, Torres-Mora J. Selected giant cell rich lesions of the temporal bone. *Head and Neck Pathology*. 2018 Sep;12(3):367-77.
2. Khan M, Quadri S, Kazmi A, Kwatra V, Ramachandran A, Gustin A, Farooqui M, Suriya S, Zafar A. A comprehensive review of skull base osteomyelitis: diagnostic and therapeutic challenges among various presentations. *Asian journal of neurosurgery*. 2018 Dec;13(04):959-70.
3. Kumar S, Kumar A, Gadhavi H, Maheshwari V. Tubercular skull base osteomyelitis in an immunocompetent individual: A rare entity ". *Interdisciplinary Neurosurgery*. 2021 Jun 1;24:100816.
4. Chandler JR. Malignant external otitis and osteomyelitis of the base of the skull. *The American journal of otology*. 1989 Mar 1;10(2):108-10.

Copyright: © 2023 Sumit Sharma., et al. This is an open-access article distributed under the terms of the Creative Commons Attribution License, which permits unrestricted use, distribution, and reproduction in any medium.

Correspondence

Dr. M. Ravi Sankar
Associate Professor Neurotology
Department of Neurosurgery
SGPGIMS
Raebareli Road
Lucknow, UP.226014
dravisankarpgi@gmail.com

How to cite this article

Kumar A. et al; Skull Base Osteomyelitis In An Immunocompetent Host: A Rare And Atypical Presentation; *UPJOHNS*; June 23; 11(1); page 52-55
DOI: <http://doi.org/10.36611/upjohns/volume11/Issue1/9>
Orchid Id: <https://0000-0001-5871-8187>



This work is licensed under a Creative Commons Attribution 4.0 International License
Copyright © 2020 –UPJOHNS